

Langerhans cell histiocytosis of the ear

Usama M Rashad¹, Al Hussein Awad Ali² and Mahmoud R. Hussein³, *

^{1,2}Departments of ENT (Sohag University) and ³Pathology (Assuit University)

* Corresponding author: Mahmoud R. A. Hussein MD, MSc, Department of Pathology, Faculty of Medicine and Assuit University Hospitals, Assiut University, Assiut, Egypt

Email address: frcpath17@gmail.com

Abstract:

Langerhans cell histiocytosis (LCH) is a rare neoplastic lesion characterized by accumulation of cells having major phenotypic features of skin Langerhans cells. It usually affects young children but rare cases were also reported in adults. The clinical spectrum of LCH includes Letterer–Siwe disease, Hand–Schüller–Christian disease, eosinophilic granuloma, Langerhans cell sarcoma as well as intermediate and poorly elucidated forms. Here we address the clinicopathologic features and histogenesis of this condition.

Keywords: Ear, temporal bone, Histiocytosis X, tumor

1 Clinicopathologic features of LCH:

In 1893, Alfred Hand was the first to report a case of histiocytosis. In 1941, Farber described this condition and reported the overlap among diseases that would later be termed histiocytosis X [1]. Langerhans' cell histiocytosis (LCH), previously known as histiocytosis X, is a poorly understood histiocytic disorder. The spectrum of disease process (Letterer–Siwe disease, Hand–Schüller–Christian disease, eosinophilic granuloma, Langerhans cell sarcoma as well as intermediate and poorly elucidated forms) ranges from the localized form with good outcome to an acute systemic form with a poor outcome. Letterer–Siwe disease is an acute disseminated form of the disease characterized by extensive cutaneous lesions (weeping erythematous eruptions), hepatosplenomegally, lymphadenopathy, fever, anemia, lymphadenopathy and osteolytic bony lesions [2]. Hand–Schüller–Christian

disease is a chronic form of the disease characterized by the triad of bone lesions, diabetes insipidus, and exophthalmos as well as weeping erythematous eruptions, papulonodular or granulomatous ulcerations. Eosinophilic granuloma is a localized form characterized by the presence of cutaneous lesions (nodulo-ulcerative lesions), lung nodules or bony osteolytic lesions [3]. The term “Langerhans cell sarcoma” is used for cytologically malignant cases that have an aggressive clinical behavior [4]. LCH may be associated with malignant lymphoma, leukemia, Myelodysplastic syndrome and hemophagocytic syndrome.

2 Histogenesis:

LCH has been previously considered as a reactive polyclonal disease of immune regulation and not a true neoplasm. Recent

reports, however, has revealed LCH as a clonal proliferation, and therefore attested to its neoplastic nature [5]. Badalian-Very et al reported the oncogenic BRAF V600E mutation in 35 of 61 archived specimens. TP53 and MET mutations were also observed in one sample each. Langerhans cells stained for phospho-mitogen-activated protein kinase kinase (phospho-MEK) and phospho-extracellular signal-regulated kinase (phospho-ERK) regardless of mutation status. The presence of BRAF mutations in LCH confirm that it is a neoplastic process that may respond to RAF pathway inhibitors [6]. The development of LCH may be linked to cytokine cascade (interleukin-3/IL-3, IL-7, granulocyte-macrophage colony-stimulating factor (GM-CSF); the lymphocyte regulatory cytokines IL-2, IL-4, and IL-10; the inflammatory regulators IL-1alpha and tumor necrosis factor-alpha (TNF-alpha); and the effector cell-activating cytokines IL-5 and interferon-gamma (IFN-gamma) through recruitment, maturation, and proliferation of LCH cells. These cytokines seem to be involved in the development of other characteristic features of LCH, such as fibrosis, necrosis, and osteolysis [7]. Interestingly, Human herpesvirus-6 (HHV-6) and Epstein-Barr virus have been detected in some cases [8]. The serum S100-b level is elevated in this disease and may prove to be a useful marker to monitor the progress of the disease [9].

3 Langerhans cell histiocytosis of the ear:

LCH usually affects young children, some adolescents, and a few young adults. The classic presentation of the head and neck region involves lytic lesions of bone, particularly of the skull. Other common sites include middle ear and temporal bone. On radiology, the lesions appear as single or multiple sharply circumscribed lytic lesions [10]. This disease is easily misdiagnosed as mastoiditis, otitis media and otitis externa [11]. Treatment options include excision (curettage), low dose radiation therapy or chemotherapy (if systemic process). CT plays an important role in the diagnosis of

LCH of the skull bones as it can accurately identify bone destruction, soft tissue involvement and intra-cranial histiocytosis [1]. Surgical excision of the tumor represents the treatment of choice whereas irradiation is used for inaccessible or incompletely resected lesions [5]. Chen et al examined the clinicopathologic features of LCH of the temporal bone in 22 patients. A single patient belonged to a multisystem high-risk group, three cases to the multisystem low risk group, and 18 cases to the single system group. Ear manifestation and osteolytic lesions of the temporal bones with extensive osteolytic destructions (CT findings). The misdiagnosis rate was 72.7%. Twenty-two cases were received different combined modality therapies. Following up 1 - 15 years, 21 cases were survival and 1 case dead, while 5 cases showed residual of insipidus, dwarfism, epilepsy or unilateral serious hearing loss [10].

4 Expert commentary:

Langerhans' cells are specialized histiocytes with immune functions similar to other dendritic cells and macrophages. The pathophysiology of LCH is poorly understood. Although the etiology of LCH is unclear, several theories exist regarding this condition. Pathologic Langerhans' cells are thought to be derived from precursor cells or through alteration of normal histiocytes.

5 Five-year view:

Identification of a putative myeloid progenitor in the ontogeny of LCs [12], together with the detection of a rapidly accelerated fibrosarcoma isoform B (BRAF)^{V600E} gain of-function mutation [6], suggest that LCH may be a myeloid neoplasm. The pathogenic role of the intralesional "cytokine storm" [7] in the progression of LCH provides new opportunities for targeted therapy, contributing to change the clinical management of patients. Any lytic lesion of the temporal bone identified by radiology should raise suspicion for LCH.

6 Key issues:

LCH has a wide range of clinical outcomes. Some cases of LCH are self-limited, whereas others affect multiple organs and cause significant morbidity and mortality. The outcome of the disease depends upon the age of the patient, the extent of the disease and the magnitude of organ involvement.

Reference annotations:

Ayadi K, Driss N, Hattab N, et al. [A rare cause of multiple lacunae of the cranial vault and temporal bone in adults: histiocytosis X]. *Journal de radiologie*. 1994;75:433-435.

The skull bones, especially the temporal bone, are involved in LCH [1]

Badalian-Very G, Vergilio JA, Degar BA, et al. Recurrent BRAF mutations in Langerhans cell histiocytosis. *Blood*. 2010;116:1919-1923.

Oncogenic BRAF V600E mutation were detected in some cases of LCH[6]

Case Report:

A three and half-year-old boy presented to the ENT OPD with history of recurrent attacks of right sided blood tinged ear discharge four months ago without any history of prior common cold or chronic nasal obstruction. There was a history of left eye protrusion two months ago, polyurea, polydipsia and frequent teeth loss. The patient's general condition was fine. ENT examination revealed normal nasal, oral and pharyngeal condition.

The left ear examination revealed no abnormality. Right ear examination showed that the right external auditory canal is filled with pale granulation tissues obscuring the view of the tympanic membrane.

The right post auricular area was minimally diffusely swollen and tender. Eye examination showed left axial forward proptosis without limitation of eye movements. Chest and heart were clinically free. HRCT temporal bone revealed soft tissue density swelling filling the right mastoid with erosion of the dural and sinus plates and erosion of the posterior meatal wall bone with extension of the swelling to fill the external auditory canal (Figure 1).

Differential diagnosis included lymphoma, sarcomas (including rhabdomyosarcoma), Extraskelatal Ewing's sarcoma/Primitive neuroectodermla tumor, synovial sarcoma, LCH or a metastatic disease. Biopsy was taken from the granulation tissues in the external auditory canal. On histology, sections showed a cellular lesion composed of clusters of Langerhans cells, which have moderate eosinophilic cytoplasm, kidney-shaped nuclei with indentations, vesicular chromatin with small nucleoli.

These neoplastic cells were admixed with inflammatory cell infiltrate including neutrophils, plasma cells, lymphocytes, variable foamy histiocytes and multinucleated giant cells. The neoplastic cells were reactive for S100, and CD1a. Negative stains included Myogenin, CD45 and synaptophysin. The reactive histiocytes and the multinucleated cells are reactive CD68. The diagnosis of LCH was established.

Treatment consisted of induction therapy 6 cycles, one cycle every week of vinblastin a steroid followed by maintenance therapy for one year, one cycle every 21 days (single dose of vinblastin and 5 days of steroids). Follow-up of the patient without complications or recurrence for 24 months was observed.

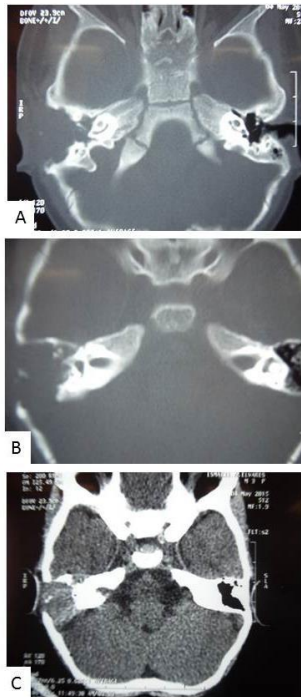


Figure 1: Radiological findings of Histiocytosis X.

A-B) HRCT temporal bone, bone window showing bone eroding lesion filling the right mastoid cavity with erosion of the posterior meatal wall bone with extension of the swelling to fill the external auditory canal radicalizing the mastoid cavity.

C): HRCT temporal bone, soft tissue window showing filling the right mastoid cavity with erosion of the dural and sinus plates and erosion of the posterior meatal wall bone with extension of the swelling to fill the external auditory canal.

Reference:

[1] Ayadi K, Driss N, Hattab N, et al. [A rare cause of multiple lacunae of the cranial vault and temporal bone in adults: histiocytosis X]. *Journal de radiologie*. 1994;75:433-435.

[2] Zhang RR. [Letterer Siwe disease in an adult: a case report]. *Zhonghua xue ye xue za zhi = Zhonghua xueyexue zazhi*. 2012;33:758.

[3] Bhargava D, Bhargava K, Hazarey V, Ganvir SM. Hand-Schuller-Christian disease. *Indian journal of dental research* :

official publication of Indian Society for Dental Research. 2012;23:830-832.

[4] Nakayama M, Takahashi K, Hori M, et al. Langerhans cell sarcoma of the cervical lymph node: a case report and literature review. *Auris, nasus, larynx*. 2010;37:750-753.

[5] Cajade Frias JM, Cajade Bao D, Lozano Ramirez A, Castro Vilas C, Vaamonde Lago P, Labella Caballero T. [Unifocal eosinophilic granuloma of the temporal bone (Langerhans cell histiocytosis)]. *Acta otorrinolaringologica espanola*. 2000;51:525-529.

[6] Badalian-Very G, Vergilio JA, Degar BA, et al. Recurrent BRAF mutations in Langerhans cell histiocytosis. *Blood*. 2010;116:1919-1923.

[7] Egeler RM, Favara BE, van Meurs M, Laman JD, Claassen E. Differential In situ cytokine profiles of Langerhans-like cells and T cells in Langerhans cell histiocytosis: abundant expression of cytokines relevant to disease and treatment. *Blood*. 1999;94:4195-4201.

[8] Csire M, Mikala G, Jako J, et al. Persistent long-term human herpesvirus 6 (HHV-6) infection in a patient with langerhans cell histiocytosis. *Pathology oncology research* : POR. 2007;13:157-160.

[9] Ugurel S, Pfohler C, Tilgen W, Reinhold U. S100-beta serum protein--a new marker in the diagnosis and monitoring of Langerhans cell histiocytosis? *The British journal of dermatology*. 2000;143:201-202.

[10] Chen L, Wang WQ, Xu H, Chi FL. [Langerhans cell histiocytosis of the temporal bone: 22 cases analysis]. *Zhonghua er bi yan hou tou jing wai ke za zhi = Chinese journal of otorhinolaryngology head and neck surgery*. 2010;45:212-216.

[11] Coleman MA, Matsumoto J, Carr CM, Eckel LJ, Nageswara Rao AA. Bilateral temporal bone langerhans cell histiocytosis: radiologic pearls. *The open neuroimaging journal*. 2013;7:53-57.

[12] Allen CE, Li L, Peters TL, et al. Cell-specific gene expression in Langerhans cell histiocytosis lesions reveals a distinct profile compared with epidermal Langerhans cells. *Journal of immunology*. 2010;184:4557-4567.
